

## Review on Observation and Treatment of Alopecia

1.kalaskar kashmiri machhindra , Proff.Jaydeep.Pawar. Dr. Sunil Nirmal

College name. Hon. Shri. BabanraoPachputeVichardhara Trust Group of Institutions, Faculty of Pharmacy,

Submitted: 10-04-2023

Accepted: 20-04-2023

### AIM-

Aim-Review On Observation And Treatment Of Alopecia

### OBJECTIVE:

To develop guidelines for the diagnosis, evaluation, assessment, response criteria, and end points for alopecia areata.

### I. INTRODUCTION:

Hair loss, also known as alopecia or baldness, refers to a loss of hair from part of the head or body. Typically at least the head is involved.

Alopecia areata (AA) is a common cause of non scarring alopecia that occurs in a patchy, confluent or diffuse pattern. It may involve loss of hair from some or all areas of the body, usually from the scalp (Odom, 2006). In 1–2% of cases, the condition can spread to the entire scalp (Alopecia totalis) or to the entire epidermis (Alopecia universalis).

The psychology of hair thinning is a complex issue. Hair is considered an essential part of overall identity: especially for women, for whom it often represents femininity and attractiveness. Men typically associate a full head of hair with youth and vigor.

Although they may be aware of pattern baldness their family, many are uncomfortable talking about the issue. Hair thinning is therefore a sensitive issue for both sexes. For sufferers, it can represent a loss of control and feelings of isolation.

People experiencing hair thinning often find themselves in a situation where their physical appearance is at odds with their own self-image and commonly worry that they appear older than they are or less attractive to others. Psychological problems due to baldness, if present, are typically most severe at the onset of symptoms.

Common types include male- or female-pattern hair loss, alopecia areata, and a thinning of hair known as telogen effluvium. The cause of male-pattern hair loss is a combination of genetics and male hormones; the cause of female pattern hair loss is unclear; the cause of alopecia areata is autoimmune; and the cause of telogen effluvium is typically a physically or psychologically stressful event. Telogen effluvium is very common following pregnancy.

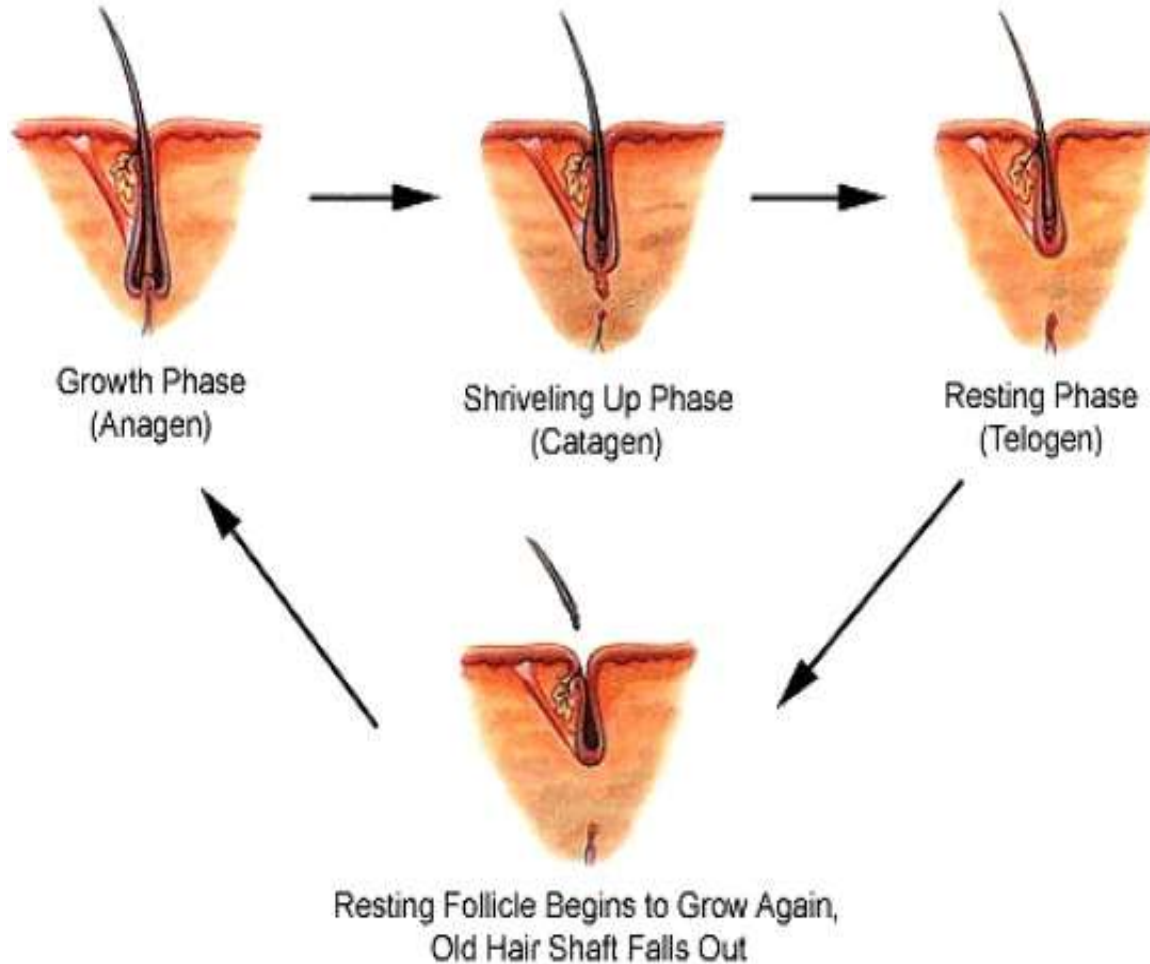
Less common causes of hair loss without inflammation or scarring include the pulling out of hair, certain medications including chemotherapy, HIV/AIDS, hypothyroidism, and malnutrition including iron deficiency. Causes of hair loss that occurs with scarring or inflammation include fungal infection, lupus erythematosus, radiation therapy, and sarcoidosis. Diagnosis of hair loss is partly based on the areas affected.

Dynamics of hair loss:

Hair follicle growth occurs in cycles (Fig. 1). Each cycle consists of a long growing phase (anagen), a short transitional phase (catagen) and a short resting phase (telogen).

At the end of the resting phase, the hair falls out (exogen) and a new hair starts growing in the follicle beginning the cycle again. There are considerable variations in the length of the three phases, with the duration of the anagen determining the type of hair produced, particularly its length.

Normally about 100 strands of hair reach the end of their resting phase each day and fallout (Trueb, 2010). Hair loss in non scarring alopecias, including alopecia areata essentially represents a disorder of hair follicle cycling



#### Etiopathogenesis

Hair growth and maintenance depends on 3 phases of hair cycle, anagen (active growth phase), catagen (involution phase), and telogen (resting phase). The type and length of the hair depends on the anagen phase. In normal healthy individuals, hair sheds out after the resting phase when the new hair anagen growth starts (exogen). In alopecias, hair shedding occurs even before the anagen starts leaving the hair follicle empty (kenogen). Thus, AA is generally a disorder of hair cycling and is considered to be a state of kenogen. [9]

Besides genetic susceptibility, various triggering factors like stress, hormones, diet, infectious agents, vaccinations and many others were incriminated in the pathogenesis of AA. [16],[17] Stress is considered as one of the triggers, but controlled studies did not confirm this.

Emotional trauma of a family death or an accident have been reported as precipitating factors in individual cases, but there are no controlled studies proving this. Iron deficiency was noted in 24-71% of females with AA. [19]

AA was less frequently observed in people, taking diet rich in soy oil. [20] Cytomegalovirus infections and hepatitis B vaccination were implicated, but further studies failed to confirm any correlation. [10],[21] Some studies found decreased levels of zinc in the blood of AA patients, [7] and others reported conflicting results. [22] Roselino et al. reported an outbreak of AA in workers at a water treatment plant in a paper factory and was linked to long-term exposure to the chemical acrylamide. [23]

Recently, AA is considered as an autoimmune disease.

The association with other autoimmune

diseases like thyroid disease, anemia, diabetes mellitus, vitiligo, and psoriasis may be one of the causes to believe AA is an autoimmune disease. [24],[25] Hair follicle-specific antibodies are increased in peripheral blood of AA patients, especially to keratin 16 and trichohyalin. [26]

It is believed that hair follicle is an immune-privileged site. [9] In healthy hair follicle epithelium, major histocompatibility complex (MHC) class I and II molecules are not expressed and TGF- $\beta$ , IGF-1, and  $\alpha$ -MSH are more expressed. [27]

This immune privilege is collapsed in AA by the presence of increased MHC I and II complexes, decreased immunosuppressive molecules, and higher expression of adhesion molecules (ICAM-2 and ELAM-1) in the perivascular and peribulbar hair follicular epithelium, leading to perifollicular inflammation.

This peribulbar inflammation adversely affects hair follicle activity, resulting in thin dystrophic hair with miniaturization. [16] Thus, AA is considered as hair follicle-specific autoimmune disease, triggered by environmental factor in genetically susceptible individuals.

Atopic type: It begins early in life and mostly (30-75%) progresses to AT.

Autoimmune type: It is seen in middle-aged groups associated with autoimmune diseases, diabetes mellitus and progresses to AT in 10-50%.

Prehypertensive type: It is seen in young adults whose parents were hypertensive and progress fastly to AT in 40% of cases.

Common type: It affects adults aged 20-40 years and AT develops in 5-15% of cases.

### Diagnosis

Before making a diagnosis, your doctor will likely give you a physical exam and ask about your diet, your hair care routine, and your medical and family history. You might also have tests, such as the following:

Blood test. This might help uncover medical conditions that can cause hair loss.

Pull test. Your doctor gently pulls several dozen hairs to see how many come out. This helps determine the stage of the shedding process.

Scalp biopsy. Your doctor scrapes samples from the skin or from a few hairs plucked from the scalp to examine the hair roots under a microscope. This can help determine whether an infection is causing hair loss.

Light microscopy. Your doctor uses a special instrument to examine hairs trimmed at

their bases. Microscopy helps uncover possible disorders of the hair shaft.

### Treatment:-

Effective treatments for some types of hair loss are available. You might be able to reverse hair loss, or at least slow it. With some conditions, such as patchy hair loss (alopecia areata), hair may regrow without treatment within a year. Treatments for hair loss include medications and surgery.

### Symptoms

The most prominent symptom of alopecia areata is patchy hair loss. Coin-sized patches of hair begin to fall out, mainly from the scalp. Any site of hair growth may be affected, though, including the beard and eyelashes.

The loss of hair can be sudden, developing in just a few days or over a period of a few weeks. There may be itching or burning in the area before hair loss. The hair follicles are not destroyed and so hair can re-grow if the inflammation of the follicles subsides. People who experience just a few patches of hair loss often have a spontaneous, full recovery without any form of treatment.

About 30 percent of individuals who develop alopecia areata find that their condition either becomes more extensive or becomes a continuous cycle of hair loss and regrowth.

About half of patients recover from alopecia areata within 1 year, but many will experience more than one episode. Around 10 percent of people will go on to develop alopecia totalis or alopecia universalis.

Alopecia areata can also affect the fingernails and toenails, and sometimes these changes are the first sign that the condition is developing. There are a number of small changes that can occur to nails:

(Image add)

- pinpoint dents appear
- white spots and lines appear
- nails become rough
- nails lose their shine
- nails become thin and split
- Additional clinical signs include:

Exclamation mark hairs: This occurs when few short hairs that get narrower at their bottom and grow in or around the edges of bald spots.

Cadaver hairs: This is where hairs break before reaching the skin surface.

White hair: This may grow in areas affected by hair loss.

#### **Medication:**

Patients with more than 50% hair loss

1. Topical immunotherapy with Diphencyprone.
2. Minoxidil 5% solution and super-potent topical corticosteroids
3. Combination of Minoxidil 5% solution and Anthralin.
4. PUVA
5. Systemic corticosteroid therapy (rarely).

For children, under the age of 10 years, treatment options

#### **Minoxidil (Rogaine).**

Over-the-counter (nonprescription) minoxidil comes in liquid, foam and shampoo forms. To be most effective, apply the product to the scalp skin once daily for women and twice daily for men. Many people prefer the foam applied when the hair is wet. include Minoxidil 5% solution with or without topical mid-potent corticosteroids or short contact Anthralin therapy

If your hair loss is caused by an underlying disease, treatment for that disease will be necessary. If a certain medication is causing the hair loss, your doctor may advise you to stop using it for a few months.

Medications are available to treat pattern (hereditary) baldness. The most common options include:

**Minoxidil(Rogaine).** Over-the-counter (nonprescription) minoxidil comes in liquid, foam and shampoo forms. To be most effective, apply the product to the scalp skin once daily for women and twice daily for men.

Many people prefer the foam applied when the hair is wet.

Products with minoxidil help many people regrow their hair or slow the rate of hair loss or both. It'll take at least six months of treatment to prevent further hair loss and to start hair regrowth. It may take a few more months to tell whether the treatment is working for you. If it is helping, you'll need to continue using the medicine indefinitely to retain the benefits.

Possible side effects include scalp irritation and unwanted hair growth on the adjacent skin of the face and hands.

#### **Finasteride (Propecia).**

This is a prescription drug for men. You take it daily as a pill. Many men taking finasteride experience a slowing of hair loss, and some may show new hair growth.

It may take a few months to tell whether it's working for you. You'll need to keep taking it to retain any benefits. Finasteride may not work as well for men over 60.

Rare side effects of finasteride include diminished sex drive and sexual function and an increased risk of prostate cancer. Women who are or may be pregnant need to avoid touching crushed or broken tablets.

#### **•Diphenylcyclopropenone:**

A topical drug that has been successful in treating alopecia areata in some people.

#### **•Squaric acid dibutylester:**

This is also used to treat alopecia areata.

#### **•Steroids:**

These help calm down the immune response and inflammation.

For children older than 10 years of age, treatment options are based on the amount of hair loss.

**Injections of corticosteroids:** To help your hair regrow, your dermatologist will inject this medication into the bald areas. These injections are usually given every 4 to 8 weeks as needed. This is considered the most effective treatment for people who have a few patches of hair loss. **Minoxidil:** can help you keep the hair growth stimulated by another treatment. You will need to apply it 2 to 3 times a day. It's helpful for the scalp, beard area, and eyebrows. **Corticosteroids:** You apply this medication to the bald spots once or twice a day as instructed by your dermatologist. This medication tends to be less effective in adults than in children for hair regrowth. **Anthralin:** You apply this medication to the bald spots, let it sit on the skin for as long as your dermatologist says, and then wash it off. best results, you'll also use minoxidil.

#### **•Corticosteroids**

Corticosteroids, because of their anti-inflammatory activity, have been the mainstay of therapy for AA. They have been used topically, orally, and parenterally. Different forms of topical steroids are used with variable efficacy. Flucinolone acetonide 0.2% cream, 0.1% betamethasone valerate foam, 0.05%

betamethasone dipropionate lotion, 0.1% halcinonide, 0.05% clobetasol ointment/foam have been used with a success range of 28.5% - 61%. [63]

It is recommended to use 1 cm beyond the involved area. Relapses were seen in 37.5% of the responders despite continuation of treatment. [63] Despite variable efficacy, topical steroids are preferred first choice in the treatment of AA because of ease of application, especially in children. Midpotent topical steroids are frequent choice in children. [64]

Folliculitis, telangiectasia, and atrophy can occur. [64] They can be applied alternate day or 5 days a week to prevent atrophy. [65] Application under occlusion increases the potency of topical corticosteroids and in turn side effects.

Kar et al. reported 60% success with 200 mg of prednisolone once-weekly for 3 months with a observational period for another 6 months. [81] Some other studies showed cosmetic regrowth in 58-82% of patients with 300 mg oral prednisolone once-monthly for 3-6 months. [84] Pasricha has reported remarkable hair growth in one patient, refractory to other therapies with oral mini pulse, betamethasone 5 mg given as a single oral dose after breakfast on two consecutive days every week for 6 months. [85] In another study by Khaitan et al., 75% of extensive AA patients showed acceptable hair growth with betamethasone oral mini pulse. [86]

### Topical Immunotherapy

Topical immunotherapy is based on the principle of inducing allergic contact dermatitis by applying potent contact allergens to the affected skin. It appears that these contact sensitizers act through immunomodulation of the skin and its appendages. [5] Dinitrochlorobenzene (DNCB) was the first sensitizer used for the treatment of AA. It was found to have mutagenic effects and was not preferred. However, DNCB was found non-carcinogenic when fed in large doses in rats, mice, guinea pigs, and men. Mohan et al. reported acceptable terminal hair growth in 36% of their patients using DNCB and suggested a relook at DNCB therapy. [69] Diphenyl-cyclo-propenone (DPCP) and squaric acid dibutyl ester (SADBE) are other contact sensitizers used in AA. The efficacy of the both agents is almost same 50-60% with a range of 9-87%. [70],[71] DPCP is preferred over SADBE as it is cheap and more stable in

acetone, which is a potent UV-absorber. DPCP is light- and heat-sensitive, and it should be stored in amber-colored bottles. [64] 2% solution is made by dissolving 20 mg in 1 ml of acetone, and further dilution can be prepared by diluting 2% solution with acetone taken in a pipette as per the concentration. [72]

The patient is first sensitized with 2% DPCP on a 4 cm<sup>2</sup> area of scalp. It is left on the scalp for 1-2 days and then washed. The scalp should be protected from the sunlight during these 2 days. Two weeks later, 0.0001% DPCP is applied on to the same side of scalp and gradually concentration is increased every week, until a mild erythema or pruritus occur. [5] Once the appropriate concentration that produced allergic reaction is established, weekly application of the same concentration is continued and left for 48 hours without exposing to sun. Treatment should be continued on the same half of the scalp until the regrowth of hair, and the second half should be treated later. Once hair regrowth is complete and maintained for more than 3 months, treatment can be gradually tapered and discontinued over a period of 9 months. [102]

If there is no response in 6 months, DPCP is less likely to be successful. Pruritus, erythema, scaling, postauricular lymphadenopathy, contact urticaria, post-inflammatory hyper- and hypopigmentation, erythema multiforme, facial edema, and flulike symptoms are some of the side effects noted with topical immunotherapy. Pigmented contact dermatitis developing after sensitization indicates poor response to contact immunotherapy. [102] Patients should be fully informed about treatment, and a written consent should be taken. Contact with the allergen must be avoided by handlers, pharmacy, medical and nursing staff and those applying, the allergen should wear gloves and aprons. It is not recommended in pregnancy as there is no data on its safety in pregnancy.

### Phototherapy

Recent Cochrane review revealed that there were not many randomized controlled studies about phototherapy in AA. [62] There are conflicting reports about efficacy of PUVA in AA. PUVA has been found to be effective in AA by decreasing the perifollicular inflammatory infiltrate. [5] Mohammad et al. has reported good or excellent response in 85% of their AA patients. [90] Turban PUVA and turban PUVASOL also have been found effective. [73],[74] PUVA in



combination with oral steroids have been found effective in recalcitrant AT and AU. [37] Mild erythema, burning and increased risk for melanoma are some of the side effects observed with PUVA. NBUVB phototherapy has been found ineffective in AA. Bayramgürler et al. from Turkey reported in a recent study that only 20% showed excellent response in severe AA, most of whom received intramuscular triamcinolone acetonide injections also and concluded that NBUVB is not an effective treatment in AA. [101] 308-nm excimer laser has shown hair regrowth in 41.5% patches of AA, but poor results were observed in AT/AU. [103] Infrared therapy as monotherapy and in combination with other modalities has shown variable success. [104] Photodynamic therapy was not effective. [105]

#### Prostaglandin Analogues

Latanoprost and bimatoprost are prostaglandin analogues, which are used in open angle glaucoma caused hypertrichosis of eyelashes and hair on the malar area as an adverse effect. [75],[76] Because of this effect, these were tried in eyelash AA and found ineffective. Though the earlier studies failed to induce hair growth, a recent trial showed a cosmetically acceptable hair growth in 45% of the latanoprost-treated group. [76] Bimatoprost has also been beneficial, and Vila et al. showed cosmetically acceptable eyelash growth in 43.2% of AU patients. [77] Transient mild eye irritation or hyperemia may occur.

#### Topical Calcineurin Inhibitors

Topical calcineurin inhibitors, tacrolimus, and pimecrolimus inhibit transcription following T-cell activation of several cytokines. They were tried in AA and were found to be ineffective. [97],[98]

#### Sulfasalazine

Sulfasalazine works as immunomodulator and immunosuppressant. It inhibits inflammatory cell chemotaxis and cytokine and antibody production. It has shown acceptable regrowth in 23%-25.6% of AA patients. [88] Aghaei et al., in an uncontrolled open label study, found complete hair regrowth in 27.3% and partial regrowth of hair in 40.9% of AA patients, and 32% developed one or other side effects. [89] Sulfasalazine can be given 0.5 g twice-daily for 1 month, followed by 1 g twice-daily for 1 month and 1.5 g twice-daily for at least 3 months. It may cause gastrointestinal distress, headache, fever, rash, hematological abnormalities, and hepatotoxicity.

#### •Cyclosporine:

An immunosuppressive drug, in combination with a steroid called methylprednisolone.

#### •Camouflage

At times, the treatments may not regrow the hair in AA/AT/AU in an attractive manner. [96] Camouflage techniques like hairpieces and hair additions may be a better option. Hairpieces could be in the form of wigs, demiwigs, toupees, cascades, and wiglets. Human hair wigs are most expensive, needs regular shampooing every 2-3 weeks and lasts only 2-3 years. Synthetic hair fibers may be a better option as they are less expensive, needs less maintenance, and lasts for 3-5 years.

Hair additions are semi-permanent, lasting about 2 months. The natural or synthetic hair fibers are attached to the existing hair by braiding, sewing, bonding, or gluing. In case of eyelashes and eyebrows, use of artificial fibers or tattooing may be offered. These techniques are not completely free of hassles and may cause traction alopecia and breakage of hair from the glue and clips. [96]

**Other medications:**



Other oral options include spironolactone (Carospir, Aldactone) and oral dutasteride (Avodart).

**Anthralin-**

Anthralin is an irritant, and its mechanism of action in AA is unknown. It is effective because of its immunosuppressive and anti-inflammatory properties by generating free radicals. [5] It is used as 0.5-1% cream with short contact therapy. It is applied daily for 20-30 minutes, for 2-3 weeks, gradually increasing contact time daily by 5 minutes up to 1 hour or till erythema and/or pruritus develops and maintained the same time of contact for 3-6 months.

Thappa et al. used it as a primary choice in the treatment of patchy AA in children <10 years of age. [65] Anthralin was found effective in 75% of patchy AA and 25% of AT patients. [64] It may produce severe irritation, folliculitis, regional lymphadenopathy, and staining of skin, clothes, and hair.

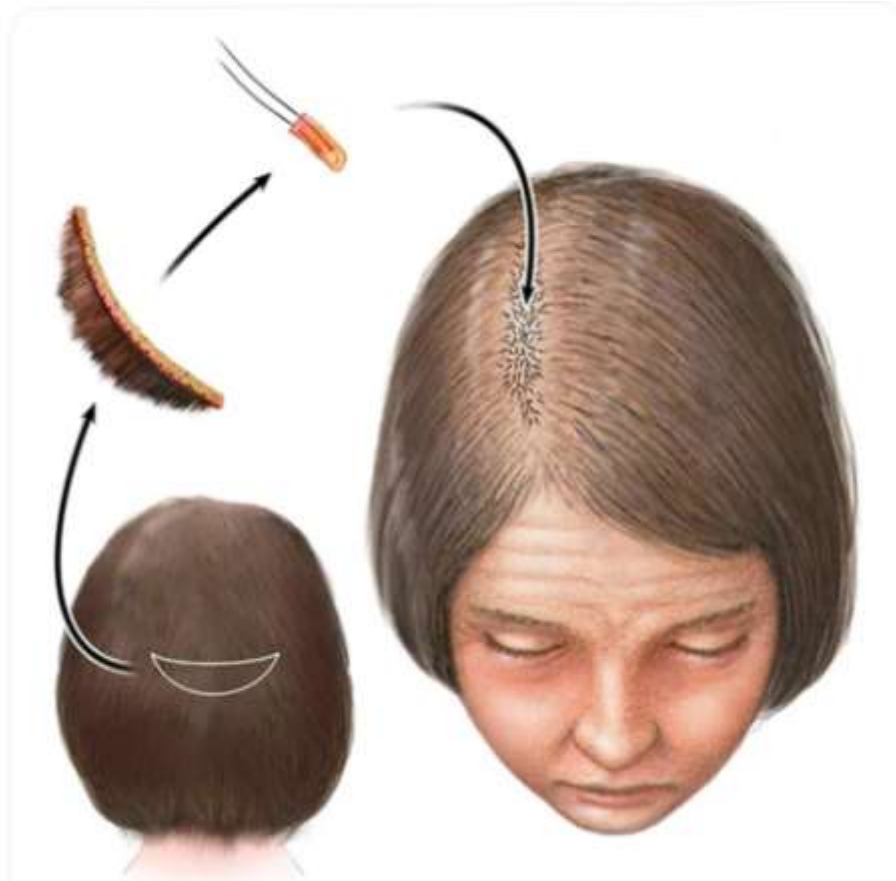**Hair transplant surgery:**

In the most common type of permanent hair loss, only the top of the head is affected. Hair transplant, or restoration surgery, can make the most of the hair you have left.

During a hair transplant procedure, a dermatologist or cosmetic surgeon removes hair from a part of the head that has hair and transplants it to a bald spot. Each patch of hair has one to several hairs (micrografts and minigrafts).

Sometimes a larger strip of skin containing multiple hair groupings is taken. This procedure doesn't require hospitalization, but it is painful so you'll be given a sedation medicine to ease any discomfort. Possible risks include bleeding, bruising, swelling and infection.

You may need more than one surgery to get the effect you want. Hereditary hair loss will eventually progress despite surgery. Surgical procedures to treat baldness are not usually covered by insurance.



### Laser therapy

Does laser treatment for hair loss work?

What it does

Low-level laser therapy — also referred to as red light therapy and cold laser therapy — irradiates photons into scalp tissues. These photons are absorbed by weak cells to encourage hair growth.

It's widely accepted that the procedure is safe, tolerable, and less invasive than hair transplant surgery.

The theory

The theory of laser treatment for hair loss is that the low-dose laser treatments invigorate circulation and stimulation that encourages hair follicles to grow hair.

•What are the positives of laser treatment for hair loss?

There are a number of reasons that advocates cite to encourage participation in the procedure, including:

- it's noninvasive
- it's painless

there are no side effects

it increases hair strength

•What are the negatives of laser treatment for hair loss?

There are a number of reasons that some people are not as positive about the procedure, such as:

It's time consuming. To see results, treatment often requires several sessions a week for a number of months. Although the number of sessions might taper off, most providers suggest that you continue treatments for the rest of your life.

It's expensive. Clinical laser treatments for hair loss can cost thousands of dollars a year.

It may not be effective. The procedure appears to be less effective for people in the advanced stages of hair loss as opposed to those in the early stages.

It can interact with certain medications. Laser therapy should not be performed on people taking medications that are photosensitizing. Photosensitizing is a chemical alteration to the skin that increases someone's sensitivity to light.

Long-term safety and effectiveness have not yet been established.



Laser devices are classified as medical devices by the FDA so they don't have the same level of scrutiny and testing that medicines go through prior to approval. Long-term safety and long-term effectiveness have not yet been established.

#### •PRP therapy-

PRP (platelet-rich plasma) therapy for hair loss is a three-step medical treatment in which a person's blood is drawn, processed, and then injected into the scalp.

Some in the medical community think that PRP injections trigger natural hair growth and maintain it by increasing blood supply to the hair follicle and increasing the thickness of the hair shaft. Sometimes this approach is combined with other hair loss procedures or medications.

There hasn't been enough research to prove if PRP is an effective hair loss treatment. However, PRP therapy has been in use since the 1980s. It's been used for problems such as healing injured tendons, ligaments, and muscles.

#### PRP therapy process

PRP therapy is a three-step process. Most PRP therapy requires three treatments 4–6 weeks apart. Maintenance treatments are required every 4–6 months.

#### Step 1

Your blood is drawn — typically from your arm — and put into a centrifuge (a machine that spins rapidly to separate fluids of different densities).

#### Step 2


After about 10 minutes in the centrifuge, your blood will have separated into in three layers:  
platelet-poor plasma

platelet-rich plasma  
red blood cells

#### Step 3

The platelet-rich plasma is drawn up into a syringe and then injected into areas of the scalp that need increased hair growth. There hasn't been enough research to prove whether PRP is effective. It's also unclear for whom — and under what circumstances — it's most effective.

According to a recent study Trusted Source, "Although PRP has sufficient theoretical scientific basis to support its use in hair restoration, hair restoration using PRP is still at its infancy. Clinical evidence is still weak."



### Causes:

The condition occurs when white blood cells attack the cells in hair follicles, causing them to shrink and dramatically slow down hair production. It is unknown precisely what causes the body's immune system to target hair follicles in this way.

While scientists are unsure why these changes occur, it seems that genetics are involved as alopecia areata is more likely to occur in a person who has a close family member with the disease. One in five people with the disease has a family member who has also developed alopecia areata.

Other research has found that many people with a family history of alopecia areata also have a personal or family history of other autoimmune disorders, such as atopy, a disorder characterized by a tendency to be hyperallergic, thyroiditis, and vitiligo.

Despite what many people think, there is very little scientific evidence to support the view that alopecia areata is caused by stress. Extreme cases of stress could potentially trigger the condition, but most recent research points toward a genetic cause.

Every day, most people lose about 100 hairs from their scalp. While the majority of people grow those hairs back, some people don't due to:

- age
- heredity
- hormonal changes
- medical conditions, such as lupus and diabetes
- poor nutrition
- side effects of a medical treatment, such as chemotherapy
- stress

Treatments to stop hair loss and possibly reverse it include:

medications such as minoxidil (Rogaine) and finasteride (Propecia)

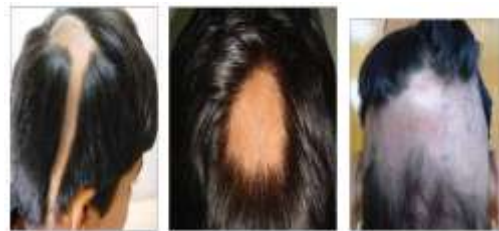### Home remedies:

As conventional treatments for alopecia are extremely limited, studies that support natural treatments for alopecia are even thinner on the ground.

There are some people that recommend rubbing onion or garlic juice, cooled green tea, almond oil, rosemary oil, honey, or coconut milk

into the scalp. While none of these are likely to cause harm, their effectiveness is also not supported by research.

Some people turn to alternative treatment methods such as acupuncture and aromatherapy, although there is little, if any, evidence to support these treatment



What is the ideal diet for Alopecia Areata?

As we learned that it is an auto-immune disease, there's a high chance that if you take care of your immunity over the long term you can prevent this condition. However, if you do contract the condition, there are ways to manage the hair loss and promote regrowth.

Consult an expert and get a proper autoimmune hair loss diet recommendation along with the medications and topical solutions for a faster recovery. Both, the treatment along with diet, plays a really critical part in either activating or lessening inflammation in the body.

Here is the recommended alopecia food diet curated by expert dermatologists at HairMD.

### Essential Vitamins for Alopecia diet:

Hair is one such body part where the nutrition reaches the last. Therefore it is important to ensure that your diet consists of all the essential nutrients needed by the hair.

The most vital nutrients and vitamins required to prevent Alopecia Areata are:

#### Biotin

– Biotin is responsible for hair growth and increasing the volume of hair.

#### Zinc

– Zinc plays an important role in hair tissue growth and repair. It also helps keep the oil glands around the follicles working properly.

#### Thiamine

– Thiamine prevents nerve damage, so the hair follicles can grow without a hurdle.

### Vitamin C

– Vitamin C strengthens the capillaries that supply blood to the hair shaft.

### Best Foods for Alopecia Areata

Some medical experts contradict the fact that diet can help in case of Alopecia but in most of the cases, people with good diet and healthy lifestyle have seen significant results in hair regrowth.

### Some of the best foods to include in Androgenic Alopecia diet are –

#### 1. Fruits and Vegetables

– Include more bright-coloured fruits and vegetables in your diet. Apples, Strawberries, Broccoli, Cauliflower, Spinach, Pineapple, Green Cabbage, Apricot among others contain antioxidants. These fruits and veggies contain antioxidants that can help reduce inflammation.

#### 2. Good oils

– In Alopecia, the scalp becomes dry and a dry scalp can not grow new hairs. Healthy fats also help in reducing the inflammatory response in the body. Increase the intake of omega-3 fatty acids found in fatty fish. All the good oils are good for your health. So, include canola oil, olive oil, and/or avocado oil in your diet. You can also use organic cold-pressed coconut oil which is tasty, nutritious and great for your hair. These oils contain the oleic acid which is an omega 9 fatty acid which decreases the inflammation.

#### 3. Nuts

– Nuts like almonds, walnuts and hazelnuts contain omega 3 fatty acids which is a key ingredient to reduce inflammation and alopecia symptoms. Have these munchies between meals or at any time of the day.

#### 4. Onions

– Onions are a very good source of antioxidants. It helps in reducing cholesterol level and the risk of heart diseases along with inflammation, which is what you need. Add more raw onions in your food, sandwiches and salads. Onion is a great option for treating Alopecia.

**Bonus Tip** – It can also be used as a natural homemade topical solution for hair. Fresh garlic and fresh onion juice are great natural ingredients to rub on your scalp and to boost circulation!

### 5. Fish

– Another food for alopecia areata, that is packed with omega 3 fatty acids is fish. Consuming wild fish can help in improving alopecia symptoms. They are very nutritious and are rich in protein and contain omega 3 fatty acids.

### 6. Protein

– Hairs is primarily made of protein. Include more protein-rich foods like eggs, meat, seafood, liver, milk, sprouts and beans in your diet.

### Bone Broth

– Bone broth in soups and stews can just do wonder in Alopecia Areata elimination diet. They are loaded with nutrients and are very easy to digest. It contains Gelatin, Collagen, Glycine, Magnesium, Phosphorous, and Calcium, all of which helps in boosting immunity, nourishing your skin, hair, nails etc. and reducing inflammation. Make this wonder food your best friend.

### Food to Avoid in Alopecia Areata Diet Plan:

#### Dairy Products

– Sometimes dairy products like Milk can trigger the immune system responses, which can worsen the AlopeciaSymptoms.

#### Excessive Caffeine

– Caffeine is actually a great hair growth stimulant when applied topically, but it isn't so good for people with hormone problems; specifically, those of us with low or heightened levels of cortisol.

#### No Nightshades

– Exclude peppers, tomatoes, eggplant, and potatoes from your alopecia areata diet as they cause inflammation.

#### Polyunsaturated fats

– Corn oil, sunflower oil etc. contains polyunsaturated fats which is an unhealthy fat. So, it is advisable to take steamed food rather than the fried ones. Bake your food or lightly saute only.

#### Sugar

– Avoid sugar in your diet as it causes inflammation. Use a small amount of honey

### Description

Alopecia areata (AA) is a complex autoimmune condition that causes non-scarring hair loss. It typically presents with sharply demarcated round patches of hair loss and may present at any age.

In this review, we review the treatment various types of pattern of hair losses and proper medication for it. epidemiology, clinical features, pathogenesis, and new treatment options of AA, with a focus on the immunologic mechanism underlying the treatment.

While traditional treatment options such as corticosteroids are moderately effective, a better understanding of the disease pathogenesis may lead to the development of new treatments that are more directed and effective against AA.

## II. CONCLUSION

AA is the common form of hair loss affecting the quality of life of many patients. Genetic susceptibility, environmental factors, and autoimmunity are the main etiological factors. GWAS studies had identified the key genes paving the way for better understanding of pathogenesis of AA. There is paucity of controlled studies regarding effective treatments of AA. Corticosteroids are the main stay in the treatment of AA. The other treatments are minoxidil, immunotherapy, and PUVA. Newer therapies are focused at T-cell mechanisms and NK-cell activating ligands.

## REFERENCE:

- [1]. review Article 2013;79:5:563-575 doi: 10.4103/0378-6323.116725 PMID: 23974575
- [2]. <https://www.sophiamichelle.com/procedure/diagnosis-of-hairloss/>
- [3]. <https://www.mayoclinic.org/diseases-conditions/hair-loss/diagnosis-treatment/drc-20372932>
- [4]. Sundberg JP, McElwee KJ, Carroll JM, King LE., Jr Hypothesis testing: CTLA4 co-stimulatory pathways critical in the pathogenesis of human and mouse alopecia areata. *J Invest Dermatol.* 2011;131:2323–4. [PMC free article] [PubMed] [Google Scholar]
- [5]. Sundberg JP, Cordy WR, King LE., Jr Alopecia areata in aging C3H/HeJ mice. *J Invest Dermatol.* 1994;102:847–56. [PubMed] [Google Scholar]
- [6]. John KK, Brockschmidt FF, Redler S, Herold C, Hanneken S, Eigelshoven S, et al. Genetic variants in CTLA4 are strongly associated with alopecia areata. *J Invest Dermatol.* 2011;131:1169–72. [PubMed] [Google Scholar]
- [7]. Rosenberg G. The mechanisms of action

- of valproate in neuropsychiatric disorders: Can we see the forest for the trees? *Cell Mol Life Sci.* 2007;64:2090–103. [PubMed] [Google Scholar]
- [8]. Lee SH, Yoon J, Shin SH, Zahoor M, Kim HJ, Park PJ, et al. Valproic acid induces hair regeneration in murine model and activates alkaline phosphatase activity in human dermal papilla cells. *PLoS One.* 2012;7:e34152. [PMC free article] [PubMed] [Google Scholar]
- [9]. Singh A, Yadav S. Microneedling: Advances and widening horizons. *Indian Dermatol Online J.* 2016;7:244–54. [PMC free article] [PubMed] [Google Scholar]
- [10]. Dhurat R, Sukesh M, Avhad G, Dandale A, Pal A, Pund P, et al. Arandomized evaluator blinded study of effect of microneedling in androgenetic alopecia: A pilot study. *Int J Trichology.* 2013;5:6–11. [PMC free article] [PubMed] [Google Scholar]
- [11]. Chandrashekar B, Yepuri V, Mysore V. Alopecia areata-successful outcome with microneedling and triamcinolone acetonide. *J Cutan Aesthet Surg.* 2014;7:63–4. [PMC free article] [PubMed] [Google Scholar]