



## A Review of Congenital Central Hypoventilation Syndrome

KEERTHANA M<sup>1</sup>, Dr.PRASOBH G R<sup>2</sup>, Dr.SUBASH CHANDRAN M P<sup>3</sup>, Dr.KARTHIKA LAL B<sup>4</sup>

<sup>1</sup>5<sup>th</sup> Year Doctor of Pharmacy Student, Sree Krishna College of Pharmacy and Research Centre, Parassala Thiruvananthapuram, Kerala, India.

<sup>2</sup>Principal of Sree Krishna College of Pharmacy and Research Centre, Parassala, Thiruvananthapuram, Kerala, India.

<sup>3</sup>Vice Principal & HOD, Department of Pharmaceutics, Sree Krishna College of Pharmacy and Research Centre, Parassala, Thiruvananthapuram, Kerala, India.

<sup>4</sup>Assistant Professor, Department of Pharmacy Practice, Sree Krishna College of Pharmacy and Research Centre, Parassala, Thiruvananthapuram, Kerala, India.

Submitted: 02-01-2023

Accepted: 10-01-2023

### ABSTRACT:

Congenital Central Hypoventilation Syndrome (CCHS) is a rare condition marked by alveolar hypoventilation caused by insufficient autonomic central ventilation control and systemic autonomic dysfunction. PHOX2B (paired-like homeobox 2B) mutations are found in the majority of CCHS patients. In recent years, the disorder has evolved from a fatal neonatal onset disorder to one with broader and milder clinical manifestations affecting children, adults, and families. In rare instances, CCHS has been linked to genes other than PHOX2B, and there are still unidentified genes that may be to blame. Currently, therapy consists of closely monitoring the progression of dysautonomic symptoms and providing continuous ventilator support.

### KEYWORDS:

Congenital central hypoventilation syndrome, PHOX2B, home mechanical ventilation, diaphragm pacing, CCHS

### INTRODUCTION:

The term "primary alveolar hypoventilation," also known as "Ondine's curse," was first observed in a newborn in 1970<sup>1</sup>. It was defined as "alveolar hypoventilation caused by an abnormality in the central nervous system's automatic control of ventilation," which could not be explained by any pulmonary, cardiovascular, neurologic, or muscular anomalies<sup>1</sup>. The disease was given the name Congenital Central Hypoventilation Syndrome (CCHS) in 1978 by authors who used phrenic nerve stimulation as a treatment option<sup>2</sup>. The clinical features of CCHS are well described: central hypoventilation caused by abnormally reduced or absent ventilatory responses to hypercapnia and hypoxia, as well as associated autonomic dysfunction manifestations such as Hirschsprung disease (HD) and neural crest tumors<sup>5</sup>.

### **EPIDEMIOLOGY:**

CCHS is a rare condition, with an estimated incidence of 1/148,000-1/200,000 live births and a prevalence of 1/500,000 people. Over 1,000 cases have been reported worldwide, although the incidence is expected to be higher<sup>6</sup>. In France, it is thought to affect one in 200,000 live births, whereas in Japan, it affects one in 148,000<sup>5</sup>.

### **ETIOLOGY:**

CCHS is caused by mutations in the PHOX2B gene<sup>4</sup>. The PHOX2B gene codes for a protein that is essential during development prior to birth<sup>4</sup>. The PHOX2B protein helps support the formation of nerve cells and regulates the process by which the neurons mature to carry out specific functions (differentiation)<sup>4</sup>. The protein is active in the neural crest, which is a group of cells in the early embryo that give rise to many tissues and organs<sup>4</sup>. Neural crest cells migrate to form parts of the autonomic nervous system, many tissues in the face and skull, and other tissue and cell types<sup>4</sup>.

### **CLINICAL PRESENTATION:**

<sup>6</sup>The following signs and symptoms may appear in new-borns with CCHS:

- Poor breathing or complete loss of spontaneous breathing, especially during sleep
- Abdominal pupils
- Inability to feed due to decreased intestinal motility and acid reflux
- Lack of or deteriorated bowel function (Hirschsprung's disease)

### **PATHOPHYSIOLOGY:**

To maintain adequate ventilation, the respiratory load must be sufficiently addressed by ventilatory muscle power and central respiratory drive (Figure 1A)<sup>6</sup>. In CCHS, the central drive declines more while sleeping than while awake. As a result, the scales are tilted to the left<sup>8</sup>. Insufficient ventilation or respiratory failure will happen if the central respiratory drive is insufficient to overcome the respiratory load (Figure 1B)<sup>6</sup>. Instead of problems in the chemoreceptors themselves, the physiologic ventilatory control abnormality in CCHS appears to be in the integration of chemoreceptor information to central ventilatory controllers. Ventilation in CCHS is influenced by the degree of physical activity<sup>10</sup>. When CCHS patients are not moving, such as when reading, doing math problems, or playing video games, their ventilation decreases<sup>8</sup>. Severe gas exchange problems in CCHS patients who are fully ventilator dependent<sup>7</sup>.

Breathing is a rhythmic motor behaviour driven by a central pattern generator (CPG) located in the ventral medulla, which feeds onto the motor neurons that innervate respiratory muscles<sup>8</sup>. This respiratory neurons are distributed in a ventrolateral column extending from the facial nucleus (nVII) to the spinal cord and subdivided

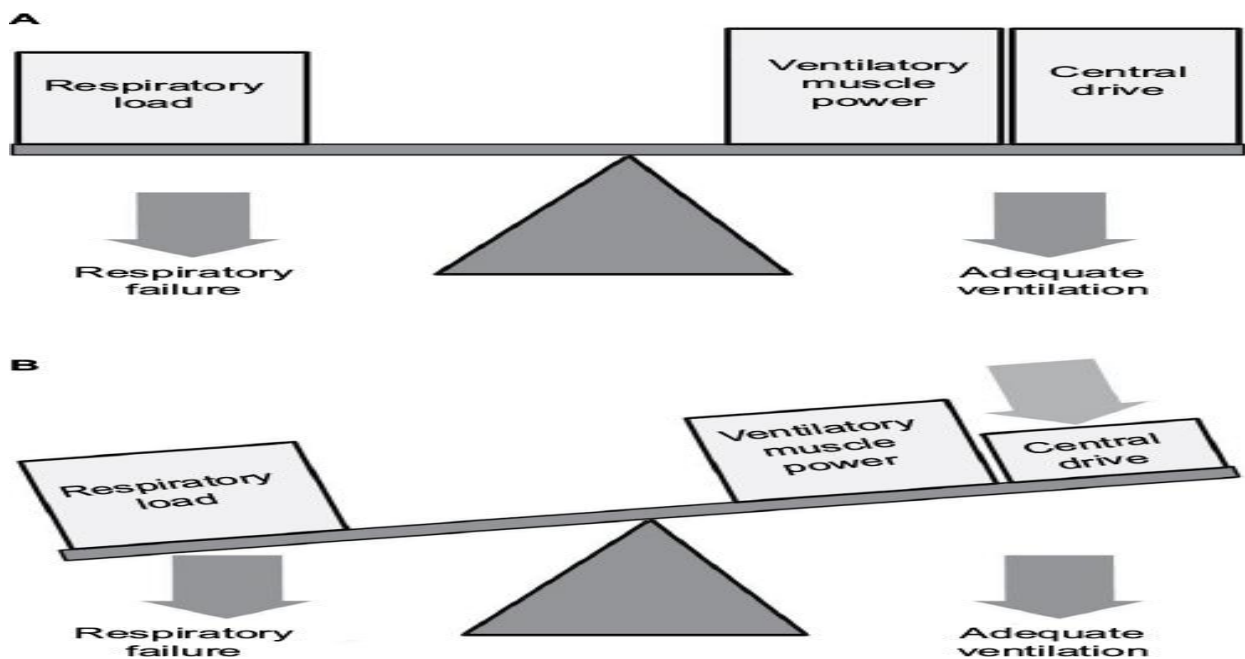
into compartments that differ in connectivity and function<sup>7,8</sup>. The best-characterized component of the CPG is the pre-Bötzinger complex (preBötC), whose oscillatory activity entrains and is an essential source of respiratory rhythm<sup>8</sup>.

There is also a small group of neurons in the rostro-ventral medulla that represents an essential site for breathing because it's responsible both for a normal respiratory rhythm in the fetal and neonatal period and for the tonic drive afforded by pCO<sub>2</sub> throughout life<sup>7</sup>. Depending on the developmental stage and its electrophysiological properties, this group of cells has been termed in different ways although they are a single entity: retrotrapezoid nucleus (RTN) in the adult, parafacial respiratory group (pFRG) in the neonate, or embryonic parafacial group (e-pF) in the fetus<sup>10</sup>.

The general features of RTN are:

- The homeobox transcription factor Phox2b is essential for the development of RTN neurons and, in general, for the development of respiratory network.
- It has been demonstrated that the RTN area contains neurons activated by CO<sub>2</sub> in the brain, due to connections with central chemoreceptors located in the ventral surface of medulla, near respiratory centers. Moreover, they are likely able to sense pCO<sub>2</sub> level directly by themselves.

However it's important to underline that RTN neurons are not only activated by pCO<sub>2</sub> in the brain but also receive potent excitatory inputs from the carotic bodies and the aortic bodies, increasing its role of chemosensory integration centre.



#### DIAGNOSIS:

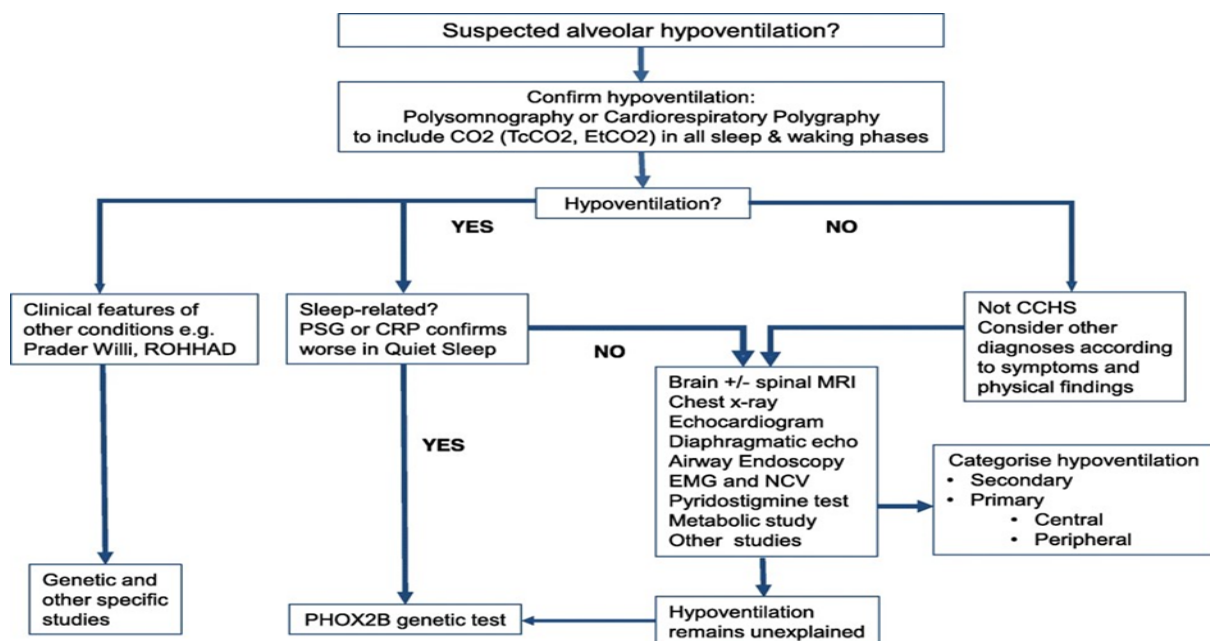
Children with CCHS develop life-threatening episodes of apnea with cyanosis, usually in the first months of life<sup>12</sup>. Medical evaluation excludes lesions of the brain, heart, and lungs but demonstrates impaired responses to build-up of carbon dioxide (hypercapnia) and decreases of oxygen in the circulation (hypoxia), the two strongest stimuli to increase breathing rate<sup>14</sup>.

Polysomnography shows that hypoventilation is most marked during slow-wave sleep<sup>16</sup>. In the most severe cases, hypoventilation is present during other nonrapid eye movement sleep stages and even wakefulness. A subset of CCHS patients are at very high risk for developing malignant neural crest-derived tumors, such as neuroblastoma.

Sequencing of the gene *PHOX2B* revealed mutations in 91% of the cases within a French cohort<sup>11</sup>.

As in many disorders that are very rare, an infant with this unusual form of sleep apnea suffers from the probability that their physician has most likely never seen another case and will not recognize the diagnosis<sup>15</sup>. In some locations, such as France, optimal management of patients, once identified, has been aided by the creation of a national registry and the formation of a network of centers<sup>7</sup>.

Alveolar hypoventilation caused by inadequate autonomic central control of breathing and general autonomic dysfunction is known as CCHS<sup>5</sup>. The diagnostic process for identifying alveolar hypoventilation is shown in below figure<sup>5</sup>.

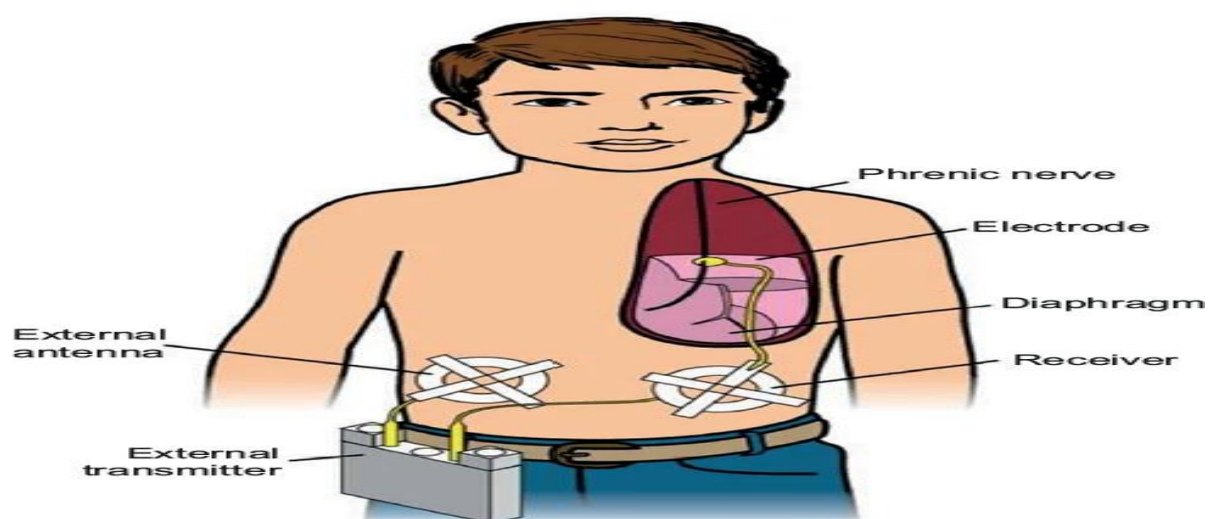


In CCHS, polysomnography reveals hypoventilation (hypercapnia and hypoxemia), which is most severe during quiet sleep (or non-rapid eye movement, NREM) compared to active sleep, and is frequently more severe during sleep than during alertness (or Rapid Eye Movement sleep, REM)<sup>13</sup>. The traditional pattern

involves a decrease in the amplitude of airflow, tidal volume, and respiratory rate. One can see central apnoea<sup>11</sup>. Both in the awake and sleeping modes, there are abnormally low or non-existent ventilatory responses to hypoxia and hypercapnia<sup>13</sup>. In order to determine the severity of hypoventilation during waking and each stage of sleep, a thorough evaluation of spontaneous ventilation during REM and NREM sleep, as well as during awake, should be carried out under medical supervision at the time of diagnosis<sup>13</sup>. For each patient, these data are crucial for respiratory therapy.

### TREATMENT:

There is currently no treatment for CCHS. Supportive artificial ventilation is the mainstay of treatment, and specific ANS dysregulation symptoms must be addressed<sup>16</sup>. In particular, everyone with CCHS will require assistance with breathing when sleeping (whether a daytime nap or night-time sleep). In extreme cases, both while the person is awake and asleep, assistance with breathing is required (day and night)<sup>16</sup>. For help breathing, infants with CCHS typically need a machine called a mechanical ventilator<sup>14</sup>. By blowing air through an airway hole created during surgery, this device aids the infant in breathing (tracheostomy)<sup>13</sup>. Some older children and adults who only experience breathing issues while they sleep may be treated with a machine that blows air via a mask over their nose or their nose and mouth (called non-invasive ventilation)<sup>3</sup>. Phrenic nerve diaphragm pacers are specialized devices that can sometimes be used to help people breathe<sup>11</sup>. For the electrodes to be placed on the phrenic nerves, which activate the diaphragm, surgery is required<sup>12</sup>. The large, thin muscle that sits just below the lungs and is utilized for breathing is known as the diaphragm<sup>12</sup>.



The mechanism of the diaphragm pacemaker is to stimulate the nerves that move the diaphragm, drawing air into the lungs<sup>13</sup>. A cardiac pacemaker might be required in a person with CCHS if they experience systoles, which are prolonged breaks in a heartbeat<sup>11</sup>. Constipation can be treated with oral medications and dietary modifications<sup>16</sup>. Surgery is required to remove Hirschsprung disease-affected sections of the bowel as well as

neural crest cell tumors<sup>11</sup>.

#### REFERENCE:

- 1] Fleming PJ, Cade D, Bryan MH, Bryan AC. Congenital central hypoventilation and sleep state. *Pediatrics*. 1980; 66(3):425–428.
- 2] Diep B, Wang A, Kun S, et al. Diaphragm pacing without tracheostomy in congenital central hypoventilation syndrome patients. *Respiration*. 2015; 89(6):534–538. 11. Spengler CM, Gozal D, Shea SA.
- 3] Straus C, Similowski T. Congenital central hypoventilation syndrome and desogestrel: a call for caution: addendum to "C. Straus, H. Trang, M.H. Becquemin, P. Touraine, T. Similowski, Chemo sensitivity recovery in Ondine's curse syndrome under treatment with desogestrel" [*Respir. Physiol. Neurobiology*. 171 (2010) 171–174].
- 4] Bachetti T, Ceccherini I. Causative and common PHOX2B variants define a broad phenotypic spectrum. *Clin Genet*. 2020; 97:103–13.
- 5] Broch A, Trang H, Montalva L, Berrebi D, Dager S, Bonnard A. Congenital central hypoventilation syndrome and Hirschsprung disease: a retrospective review of the French National Registry Center on 33 cases. *J Ped Surg*. 2019; 54:2325–30.
- 6] Bachetti T, Matera I, Borghini S, Di Duca M, Ravazzolo R, Ceccherini I. Distinct pathogenetic mechanisms for PHOX2B associated polyalanine expansions and frame shift mutations in congenital central hypoventilation syndrome. *Hum Mol Genet*. 2005; 14:1815–24.
- 7] Low KJ, Turnbull AR, Smith KR, Hilliard TN, Hole LJ, Meecham Jones DJ, Williams MM, Donaldson A. A case of congenital central hypoventilation syndrome in a three-generation family with non-polyalanine repeat PHOX2B mutation. *Pediatric Pulmonol*. 2014; 49(10):E140–3.
- 8] Paddeu EM, Giganti F, Piumelli R, et al. Sleeping problems in mothers and fathers of patients suffering from congenital central hypoventilation syndrome. *Sleep Breath*. 2015; 19:1057.
- 9] Böhm B, et al. J neurocognitive function and quality of life with congenital central hypoventilation syndrome. *Sleep Med Disorder*. 2020; 6(1):1097.
- 10] Matera I, Bachetti T, Puppa F, Di Bucca M, Morandi F, Casiraghi GM, et al. PHOX2B mutations and polyalanine expansions correlate with the severity of the respiratory phenotype and associated symptoms in both congenital and late onset central hypoventilation syndrome. *J Med Genet*. 2004; 41: 373–80.



- 11] Shaul DB, Danielson PD, McComb JG, Keens TG. Thoracoscopic placement of phrenic nerve electrodes for diaphragmatic pacing in children. *J Pediatr Surg.* 2002;37:974–8.
- 12] Weese-Mayer DE, Silvestri JM, Kenny AS, Ilbawi MN, Hauptman SA, Lipton JW, Talonen PP, Garcia HG, Watt JW, Exner G, Baer GA, Elefteriades JA, Peruzzi WT, Alex CG, Harlid R, Vincken W, Davis GM, Decramer M, Kuenzle C, Saeterhaug A, Schöber JG. Diaphragm pacing with a quadripolar phrenic nerve electrode: an international study. *Pacing ClinElectrophysiol.* 1996; 19(9):1311–9.
- 13] Verkaeren E, Brion A, Hurbault A, Chenivesse C, Morelot-Panzini C, Gonzalez Bermejo J, et al. Healthrelated quality of life in young adults with congenital central hypoventilation syndrome due to PHOX2B mutations: a cross-sectional study. *Respir Res.* 2015; 16:80.
- 14] Trang H, Bouregghda S, Denjoy I, Alia M, Kabaker M. 24-hour BP in children with congenital central hypoventilation syndrome. *Chest.* 2003; 124(4):1393–9.
- 15] Trang H, Masri Zada T, Heraut F. Abnormal auditory pathways in PHOX2B mutation positive congenital central hypoventilation syndrome. *BMC Neurol.* 2015;15:41.
- 16] Marcus CL, Bautista DB, Amihyia A, Ward SL, Keens TG. Hypercapneic arousal responses in children with congenital central hypoventilation syndrome. *Pediatrics.* 1991; 88(5):993–998.